



# Economic Analysis of Endobronchial Ultrasound (EBUS) as a Tool in the Diagnosis and Staging of Lung Cancer in Singapore

Ang SY<sup>1</sup>, Tan RWY<sup>1</sup>, Koh MS<sup>2</sup>, Lim JFY<sup>1</sup>

<sup>1</sup>SingHealth Centre for Health Services Research

<sup>2</sup>Department of Respiratory and Critical Care Medicine, Singapore General Hospital

## Introduction

Two new services are provided at Singapore General Hospital, namely: Endobronchial Ultrasound Transbronchial Needle Aspiration (EBUS-TBNA) and Endobronchial Ultrasound Transbronchial Lung Biopsy (EBUS-TBLB). The procedure is done via flexible bronchoscopy under moderate sedation at the endoscopy center in an outpatient setting. EBUS has been proven in various clinical studies to be an accurate alternative procedure in the staging and diagnosis of lung cancer and is also known to result in fewer complications while producing better sensitivity and specificity than conventional procedures.

## Methodology

Two decision analytic models (figure 1 and 2) were constructed to evaluate the cost-effectiveness of EBUS as compared to conventional diagnosis and staging modalities. The relationship between the clinical and economic implications of alternative modalities were modelled using data inputs that were relevant to the Singapore setting. Expert opinions were sought to ensure that the model appropriately reflect medical practice in Singapore. Conventional diagnostic modalities include: Transthoracic Needle Aspiration (TTNA) for peripheral lung lesions, Transbronchial Lung Biopsy (TBLB) (with fluoroscopy) and other more invasive modalities such as Video-Assisted Thoracoscopic Surgery (VATS) or thoracotomy. Conventional staging modalities include Mediastinoscopy/Medistintomy.

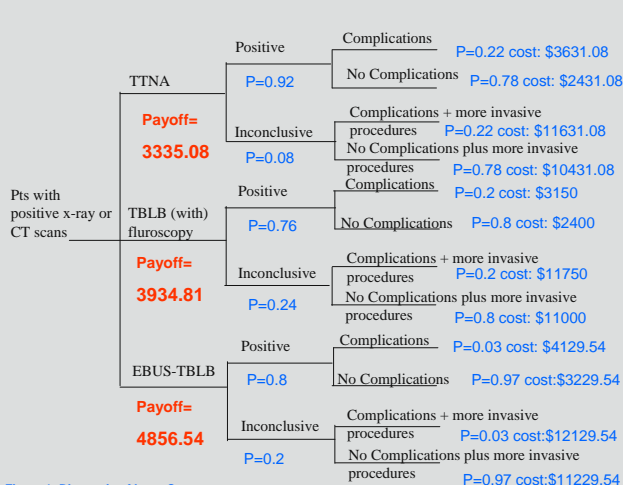


Figure 1: Diagnosis of Lung Cancer

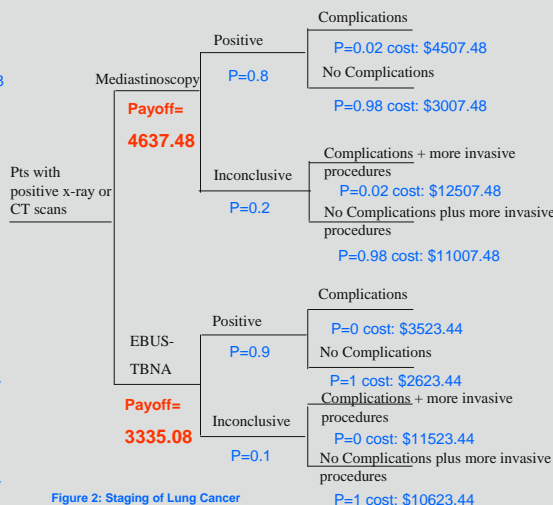


Figure 2: Staging of Lung Cancer

## Results

•For the base case analysis, TTNA was the most economical strategy (S\$3335) for the diagnosis of lung cancer as compared to the other options: TBLB (S\$3935) and EBUS-TBLB (S\$4857). However, there are limitations to TTNA including a high complication rate of 22% and up to an additional 4 days length of stay. This results in loss of productivity and income in an actively employed population. The impact of this to the society is complex and whilst important, was not included in this analysis as it is beyond the scope of this analysis.

•EBUS-TBNA resulted in a Incremental Cost Effectiveness Ratio (ICER) of S\$12,140 per positive staging of lung cancer as compared to Mediastinoscopy.

•One-way sensitivity analysis showed that TBLB was more economical than EBUS-TBLB provided the sensitivity of EBUS-TBLB remained below 90%. TTNA remained the least costly option unless almost 100% sensitivity can be achieved with EBUS-TBLB.

• For the staging of lung cancer, one-way sensitivity analysis showed that EBUS-TBNA was less costly than Mediastinoscopy, provided the sensitivity of EBUS-TBNA remained above 75%.

## Conclusion

•The use of EBUS-TBNA could result in cost savings of S\$12,140 per positive staging of lung cancer as compared to Mediastinoscopy.

•The validity of the model and its conclusion can be further verified as more patients undergo EBUS procedures and outcomes data are collected.

•Although TTNA was the most economical strategy (S\$3335) for the diagnosis of lung cancer, its main limitation lies in its suitability only for peripheral lung lesions and high complication rate.

## References

Hirose CC, Watanabe M, Estil ES, Lasker M (2005) Cost-minimization analysis of alternative diagnostic approaches in a modelled patient with non-small cell lung cancer and subcarinal lymphadenopathy. *Mayo Clinical Proceedings*, 77 pp 155-164.

Eloubeid MA, Tamhane A, Chen VK, Cerfolio R (2005) Endoscopic ultrasound-guided fine-needle aspiration in patients with non-small cell lung cancer and prior negative mediastinoscopy. *The Society of Thoracic Surgeons*, 80, pp 1231-1240.

Kramer H, Patten JWG, Post WJ, Duttman HM, Stangiers AH, Plim J, Szmajda J, Kirkenberg T, Groen H and Groen HAM (2004) Oesophageal endoscopic ultrasound with fine needle aspiration improves and simplifies the staging of lung cancer. *Thorax*, 59, pp 698-691.

Medical Services Advisory Committee (2007) Endoscopic Ultrasound Guided Fine-Needle Aspiration for the Staging of Non-cell lung cancer and the Diagnosis of Mediastinal Masses. Commonwealth of Australia.

Diagnosis and management of lung cancer: American College of Chest Physician (ACCP) Guidelines, (2<sup>nd</sup> edition) Chest 2007; 132(3 Suppl): 1S-422 S.